



# Best clinical practice guidance for prescribing dental radiographs in children and adolescents: an EAPD policy document

J. Kühnisch<sup>1</sup> · V. Anttonen<sup>2,3</sup> · M. S. Duggal<sup>4</sup> · M. Loizides Spyridonos<sup>5</sup> · S. Rajasekharan<sup>6</sup> · M. Sobczak<sup>7</sup> · E. Stratigaki<sup>8</sup> · J. W. G. Van Acker<sup>6</sup> · J. K. M. Aps<sup>9</sup> · K. Horner<sup>10</sup> · K. Tsiklakis<sup>11</sup>

Received: 24 July 2019 / Accepted: 14 November 2019  
© European Academy of Paediatric Dentistry 2019

## Abstract

**Background** The European Academy of Paediatric Dentistry (EAPD) proposes this best clinical practice guidance to help practitioners decide when and how to prescribe dental radiographs in children and adolescents.

**Methods** Four expert working groups conducted each a systematic review of the literature. The main subjects were radiation protection, intraoral dental radiography (bitewing and periapical radiographs), panoramic radiography (PR) and cone-beam computed tomography (CBCT). In addition, three workshops were held during the corresponding EAPD Interim Seminar in Chania (Crete, Greece) in 2019. On the basis of the identified evidence, all invited experts presented their findings and during the workshops aspects of clinical relevance were discussed.

**Results** Several clinical-based recommendations and statements were agreed upon.

**Conclusion** There is no or low-grade evidence about the efficacy of dental radiographic examinations in young populations. The given recommendations and rationales should be understood as best clinical practice guidance. It is essential to respect the radiological principles of an individualized and patient-specific justification. When a dental radiograph is required, its application needs to be optimized, aiming at limiting the patient's exposure to ionising radiation according to the ALADAIP principle (*As Low As Diagnostically Achievable being Indication-oriented and Patient-specific*).

**Keywords** Dental radiography · Bitewing radiography · Panoramic radiography · Cone-beam computed tomography · Child · Adolescent · Guideline

---

J. W. G. Van Acker, J. K. M. Aps, K. Horner and K. Tsiklakis are shared senior authorship.

---

✉ J. Kühnisch  
jkuehn@dent.med.uni-muenchen.de

<sup>1</sup> Department of Conservative Dentistry and Periodontology, University Hospital, Ludwig-Maximilians-Universität München, Goethestraße 70, 80336 München, Germany

<sup>2</sup> Department of Cariology, Endodontology and Paediatric Dentistry, Research Unit of Oral Health Sciences, University of Oulu, Oulu, Finland

<sup>3</sup> Medical Research Center, Oulu University Hospital and University of Oulu, Oulu, Finland

<sup>4</sup> Faculty of Dentistry, National University of Singapore, Singapore, Singapore

<sup>5</sup> Specialist Private Practice, Paediatric Dentistry, Nicosia, Cyprus

<sup>6</sup> Department of Paediatric Dentistry, PaeCoMeDiS Research Cluster, Ghent University, Ghent, Belgium

<sup>7</sup> Specialized Dental Practice, Warsaw, Poland

<sup>8</sup> Department of Orthodontics and Paediatric Dentistry, University of Basel, Basel, Switzerland

<sup>9</sup> Division of Oral Diagnostic and Surgical Sciences, University of Western Australia, Perth, Australia

<sup>10</sup> Division of Dentistry, School of Medical Sciences, Faculty of Biology, Medicine and Health, University of Manchester, Manchester Academic Health Science Centre, Manchester, UK

<sup>11</sup> Department of Oral Diagnosis and Radiology National and Kapodistrian, University of Athens, Athens, Greece

## Aim

The European Academy of Paediatric Dentistry (EAPD) proposes this best clinical practice guidance to help practitioners decide when and how to prescribe dental radiographs for diagnostic purposes and during the delivery of oral health care in children and adolescents. The current document replaces the former EAPD statement developed by Espelid et al. (2003). It provides information on prescribing dental intraoral radiography, panoramic radiography (PR) and cone-beam computed tomography (CBCT) for caries detection and assessment as well as for diagnostics in case of dental infections, dental trauma, dental anomalies, developmental disorders or pathological findings. Orthodontics, age estimation and treatment-related radiographs, e.g., in case of endodontic treatments, are not considered in this document. Similar statements for children and adolescents (AAPD 2017; Kühnisch et al. 2018) and adult patients (CDA 1999; ADA 2012; EC 2012; Goodwin et al. 2017; Horner and Eaton 2018) have been published by other academic associations and influenced the present guidance.

## Selection of the guidance topic

Numerically, dental X-ray procedures contribute about one-third of all X-ray examinations. With respect to the low mean effective doses of these procedures their contribution to the collective effective dose is, however, estimated to be 2–4% of the total collective effective dose for plain radiography (European Commission 2015). Even so, efforts should be undertaken to minimize the amount of dental radiographs and to keep exposure as low as diagnostically achievable (Le Heron 1999; Minister of Public Works and Government Services 1999; White et al. 2001; EC 2004; NRPB 2001; Valentin 2007; EC 2015) especially in children and adolescents. Modern X-ray-free imaging techniques which may replace radiography should be used whenever possible. This rationale is in line with the European Council Directive 2013/59/Euratom of 5 December 2013 laying down basic safety standards for protection against the dangers arising from exposure to ionising radiation (Council of the European Union 2013). Medical exposure is regulated in chapter VII and article 55. This article refers, first, to justification when prescribing medical radiographic examination: “Medical exposure shall show a *sufficient net benefit*, weighing the total potential diagnostic or therapeutic benefits it produces, including the direct benefits to health of an individual and the benefits to society, against the individual detriment

that the exposure might cause, taking into account the efficacy, benefits and risks of available *alternative techniques* having the same objective but involving no or less exposure to ionising radiation.” Furthermore, diagnostic radiographs shall ensure that doses are kept as low as reasonably achievable (ALARA) consistent with obtaining the required medical information (article 56). This second principle, known as optimization refers to measures of restricting the dose associated with the exposure. Therefore, the paediatric dentist needs to consider ALARA in daily practice as well. The third fundamental principle of radiation protection refers to the application of *dose limits* for occupational and public exposure. It is worth noting that there are no dose limits for patients. The Directive 2013/59/Euratom represents the most recent regulatory framework of radiation protection which is of high relevance across all European countries, and therefore, medical/dental professionals prescribing X-ray images are urged to follow its recommendations. Contrary to this, preferences for the use of dental radiographs may differ between member countries of the EAPD. This could be due to different regulations and insurance/reimbursement systems, as well as local variation in custom and practice. Educational experience at under- and post-graduate levels might also instil practices in X-ray use. From the EAPD’s point of view there is a need to summarize consensus recommendations on dental radiography prescription. Consequently, the academy identified “dental radiography” as a relevant guidance topic.

## Materials and methods

The present EAPD best clinical practice guidance was developed and agreed on at a Workshop organized by the Academy during its 11th EAPD Interim Seminar in Chania (Crete, Greece) in May 2019. The discussions were carried out by those attending three working groups consisting of invited experts and nominated delegates from the EAPD member countries. Each of the working groups was moderated by two members of the EAPD Clinical Affairs Committee (CAC). Discussions were carried out and conclusions were reached by agreement and consent, taking into account the basic principles of radiation protection, being “justification, limitation and optimization”. This document is based on ethical and practical considerations, principles in radiation protection and the comprehensive literature searches that were undertaken and presented by the invited experts (Aps et al. in press; Tsiklakis et al. in press; Horner et al. in press; Van Acker et al. in press). Relevant parameters and search terms for dental radiography in children and adolescents were considered. Following the identification of papers, the available literature was screened and studies that

met the inclusion criteria were selected. The eligible papers were carefully read and included for final analysis. In the case of insufficient or inconclusive data, recommendations for clinical practice were based upon expert opinion.

## Level of evidence and strength of recommendation

Within the presentations and during the discussions at the workshops at the EAPD Interim Seminar, a significant lack of clinical studies on the usage, efficacy and cost-effectiveness (Fryback and Thornbury 1991) of typically used dental radiographs in children and adolescents was reported. This results in mostly low-grade evidence and, therefore, expert recommendations based on clinical experience. Nevertheless, when prescribing intraoral, panoramic radiographs (PR) and cone-beam computed tomography (CBCT), the following recommendations should be taken into consideration.

## Radiation protection in paediatric dentistry

### Justification

The most efficient approach to reduce exposure to ionising radiation is strict justification. Meticulous clinical examination, the patient's ability to cooperate, information from previously taken radiographs and also the possibility of alternative non-radiographic examination options should be the key factors to determine the prescription of radiographs. Therefore, the aim of this best clinical practice guidance is to summarize clinical indicators which justify the prescription of dental radiographs. A justified radiograph should make a substantial contribution to distinguish between treatment options. Forensic imaging, e.g., for age determination or other legal purposes, radiographs for screening, or radiographic images which purely confirm clinical findings are contra-indicated with respect to the known hazards of ionising radiation.

### Optimization

The conceptual framework of "As Low As Reasonably Achievable" (ALARA) has been modified into "As Low As Diagnostically Acceptable" (ALADA, White et al. 2014). This change reflects the trade-off between image quality and radiation dose that is seen in digital X-ray imaging. This emphasizes the need for optimization, which aims to use the lowest radiation dose consistent with adequate image quality. Therefore, for each patient, the necessary exposure parameters should be appropriately modified according to patient size, importantly in the case of children and adolescents who

are smaller in size (Hidalgo Rivas et al. 2015; Pauwels et al. 2017; Brasil et al. 2019). Furthermore, some specific diagnostic tasks may require greater image resolution, and thus a higher exposure setting, than others. For example, imaging of root canals or fracture lines in teeth need a higher level of image quality than the dose needed for detection of the presence or absence of a tooth. This is why the ALADAIP (*As Low As Diagnostically Achievable being Indication-oriented and Patient-specific*) acronym has been introduced more recently (Oenning et al. 2018; Jacobs et al. 2018).

## Proposed workflow on justification and optimization

Initially, considering the individual decision-making process in detail (Fig. 1) the (paediatric) dentist has to justify the need for any radiographic examination individually on the basis of the diagnostic efficacy associated with the specific X-ray examination and the associated radiation risk, with due regard to available alternative, X-ray-free techniques. As rule of thumb can be formulated that a local dental problem in children and adolescents probably indicates an intraoral radiograph of the region of interest and that a generalized dental condition may require a PR. CBCT follows strict indications and is limited to very few clinical situations where two dimensional imaging modalities fall short in terms of diagnostic efficacy.

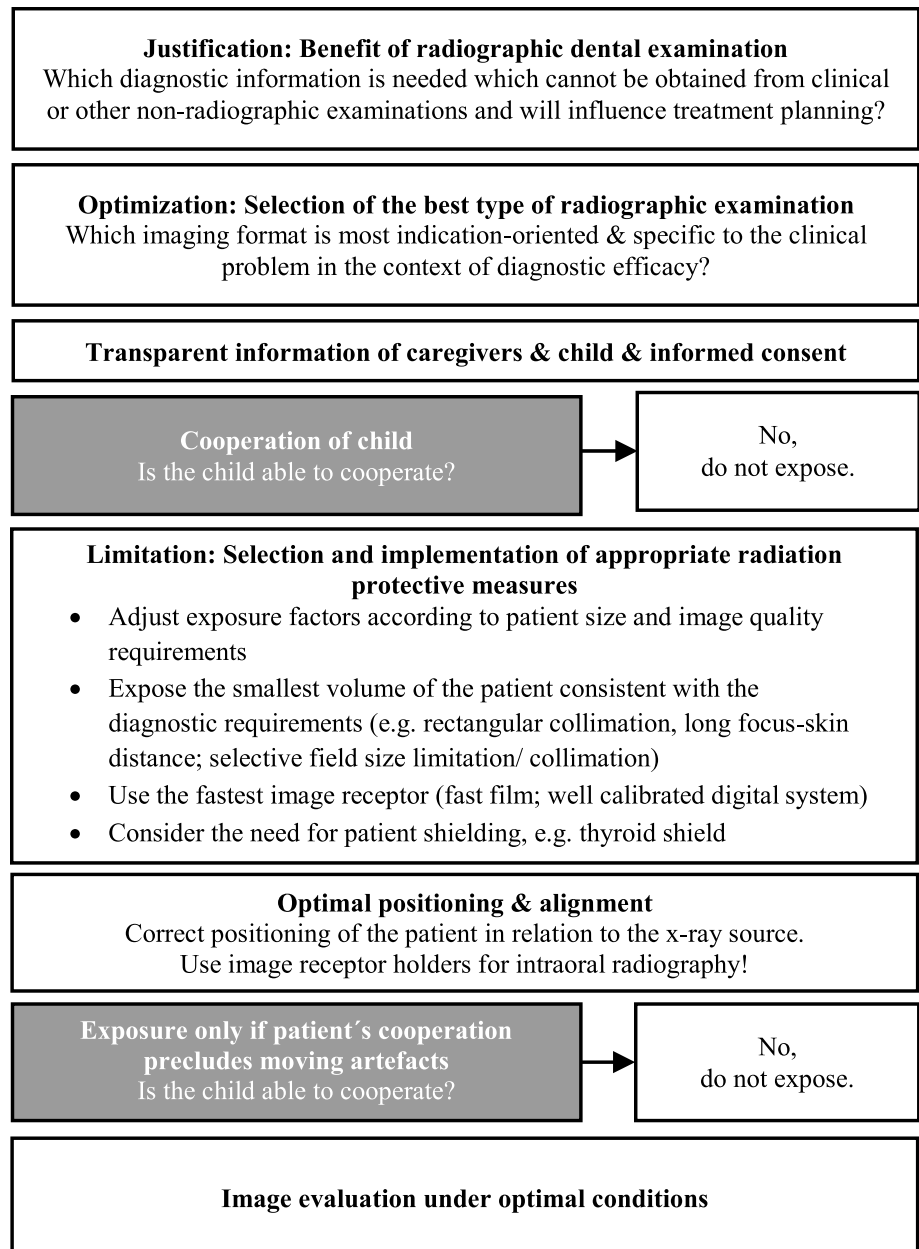
In the next step, optimisation of the X-ray examination needs to be performed according to the ALADAIP concept. Optimisation can be applied at various points along the imaging chain, starting with the X-ray machine settings (exposure factor selection), the beam size and field of view (FOV) selection (collimation), the choice of image receptor and the possible need for protective shielding. Finally, each radiographic image needs to be evaluated and assessed as precisely as possible using optimal viewing conditions.

## Recommendations on the use of protective precautions

Several radioprotective precautions may be considered when a dental radiographic examination is planned. As some of the recommendations in this document might be in disagreement with local laws and regulations it is advisable to follow primarily the country's guidelines, since the current document has no legally binding force. Adjustment of device settings or application of certain radioprotective devices should always be weighed against the therapeutic outcome of the image.

A radiograph, obtained with very low dose exposure settings, but no diagnostic value due to insufficient image quality is unjustified. The following recommendations were derived from the literature.

**Fig. 1** Workflow during pre-scription on dental radiographs in children and adolescents, taking into consideration the 3 basic principles of radiation protection: justification, optimization and limitation



For intraoral radiography:

- Rectangular collimation is highly effective in radiation dose reduction, cutting dose by at least 50%, and should be used instead of circular collimation. Preferably, it should be applied in combination with film/digital receptor holders incorporating beam-aiming devices. When film/digital receptor holders are not possible, rectangular collimation should still be considered.
- The fastest image receptor speed, e.g., F-speed film or a well-calibrated digital system, should be used as this significantly reduces the radiation dose.

- Thyroid shielding should be considered when the thyroid gland is in line of or very close to the primary beam, which is rare, e.g., maxillary occlusal views. The use of rectangular collimation is the most effective protection for the thyroid gland.

For panoramic radiographs (PR):

- FOV limitation (collimation) reduces the radiation dose effectively. The smallest FOV for the given indication should be used on an individual based level.

- Equipment with digital receptor technology could reduce radiation dose over non-digital receptors. The fastest receptor technology consistent with satisfactory diagnostic results should be used.
- The use of automated exposure control or manual adjustment of intensity (mA) can reduce the exposure dose. All of these changes should be done in consistence with sufficient therapeutic value on an individually and indication-based level.

For cone-beam computed tomography (CBCT):

- FOV limitation (collimation) reduces the radiation dose effectively. The smallest FOV for the given indication should be used on an individually based level. This is especially important considering the height of the FOV.
- The largest voxels size in relation to the treatment needs should be chosen on an individually and indication-based level.
- Change in image settings such as ultra-low dose settings, shorter exposure time, a lower amount of projections (resolution), lower beam intensity (mA), reduction of the potential (kV) and the use of automated exposure control can reduce the radiation dose. All of these changes should be done while maintaining a sufficient therapeutic value on an individually and indication-based level. Nevertheless, it is important to emphasize that some aspects of optimisation, particular selection of exposure settings in radiography, are not easy for the dentist to understand and perform, and therefore, it is highly advisable to involve wherever possible a medical physics expert. The involvement of a Medical Physics Expert is helpful and is mandatory in some countries.
- The use of a thyroid shield should be routinely used except in two situations: first, when the CBCT examination is intended to image structures below, or very close to, the axial level of the top of the shield, in which situation artefacts from the shield might affect the quality and secondly, when using tube current modulation during the scan, giving real-time feedback from detector to the exposure control. In case of using automatic exposure control based on scout images, the thyroid shield should be positioned only after the scout images have been taken (Pauwels et al. 2019).

## General recommendations

During the workshop, several more general points were discussed and acknowledged as important for daily dental practice. These aspects are summarized in this section, as they are valid for all imaging types:

- The informed consent of the responsible carer and child is needed before a dental radiograph is carried out. Each child has to be informed, in an age-appropriate way, about the aim and requirements of the chosen dental radiographic examination.
- The responsible adult and the child have to be informed about potential hazards of using ionising radiation, especially in case of CBCT. Alternative and X-ray-free examination techniques should be considered during the decision-making process. Extra exposures due to repeat examinations should be avoided.
- The performed X-ray(s), dose(s) and the corresponding diagnoses have to be documented in the patient clinical records.
- The (paediatric) dentist needs to be trained and experienced to evaluate dental radiographs. This requires profound knowledge of radiological anatomy and -pathology as well as of artefacts. In the case of performing CBCT images the whole captured volume needs to be sufficiently analysed, requiring a profound knowledge of 3D structures, and therefore, in some countries, CBCT interpretation renders the involvement of a specialist dental and maxillofacial radiologist and/or additional training for the dental practitioner mandatory.
- Incidental findings of clinical significance are rare, and therefore, screening for their possible presence cannot justify the prescription of dental radiographs.
- Imaging procedures with a longer acquisition time, e.g., PR or CBCT, are more susceptible to movement artefacts. This necessitates greater care in prescription in young(er) children. Therefore, their indication needs to be evaluated with caution in less or non-cooperative children and adolescents who are unable to keep still during the radiographic exposure.
- Children with disabilities may show difficulties in positioning and stability during imaging or those with learning disabilities may also show limited acceptance in intraoral imaging. In cases such as extraction of permanent teeth or treatment under general anaesthesia, in which imaging is essential, carers and/or comforters may assist the correct alignment of the image receptor holder and X-ray source, as long as they are provided with a protective lead/lead-equivalent apron and are not in the primary radiation beam.

## Intraoral radiography (Workshop 1)

The clinical use of some formerly used intraoral techniques or film formats, e.g., long bitewing format (2.7×5.4 cm) or occlusal radiograph (7.5×5.5 cm) is becoming more and more limited due to the digital imaging evolution. This is because, nowadays, only the phosphor storage plates come

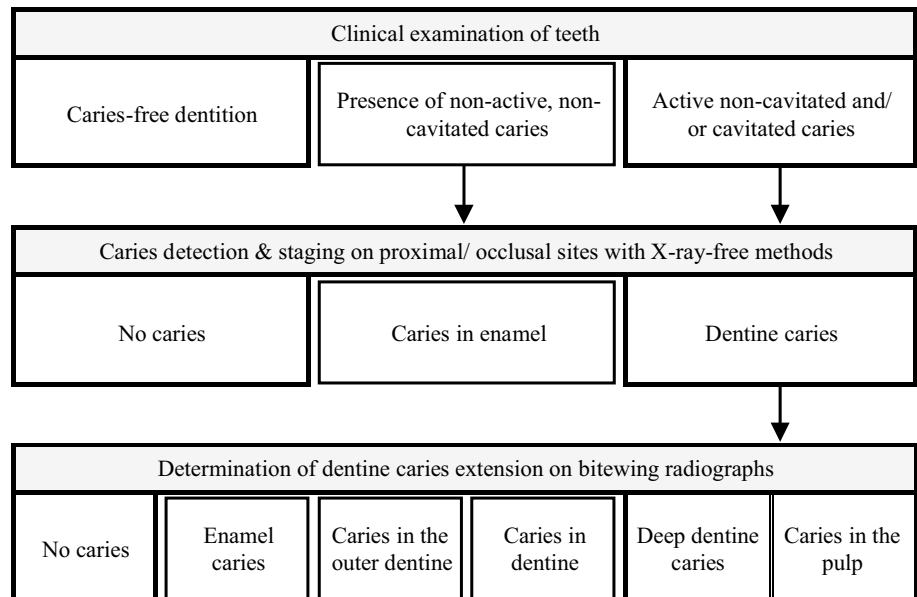
in the same sizes as the previously used analogue films. The same is true for alternative projection techniques, e.g., the oblique lateral technique. The issue of image detectors (phosphor plates versus solid-state sensors) and their inherent imaging limitations (e.g., limited occlusal radiography possibilities with solid-state sensors) were not considered in the present guidance. Therefore, recommendations were drawn only for bitewing radiographs and periapical radiographs which can be captured by commonly available intraoral image detector formats (20×30 mm or 30×40 mm).

Intraoral radiography is the preferred imaging technique for local—mostly tooth-related—dental problem(s) or

questions. The intraoral positioning of the image detector may trigger the gagging reflex and hinder an appropriate image capturing. Good cooperation of the patient, including the acceptance for intraoral placement of the image receptor holder with the image detector, has to be seen as a requirement to perform this radiographic examination. This can be expected in children most probably around the age of 4–5 years. Unfortunately, there are no comparable imaging techniques available having the same objective, with possibly better patient comfort and involving no or less exposure to ionising radiation.

The following two sections summarize clinical indicators which may justify intraoral radiographs.

**Fig. 2** Diagnosis-related justification of bitewing radiographs based on the clinical examination and results from X-ray-free diagnostic investigation. In case of non-availability of X-ray-free methods this step needs to be skipped



**Table 1** Expert recommendation on the individual spread of time intervals (in years) for the justification of the next bitewing radiographs

Suggested time intervals (year) for next bitewing radiographs		Recently detected proximal caries extend			
Patient's age (years)	Dentition	No caries	Enamel caries	Caries beyond enamel-dentin-junction	Caries in the outer third of dentin
3–7	Primary	–	~2–3	~1	~1
7–9	Mixed	–	–	~1–2	~1
10–12	Mixed	Probably no indication due to the physiological exfoliation of primary teeth			
13–16	Permanent	~3–5	~2	~1–2	~1
> 16	Permanent	~5–10	~3	~1–2	~1–2

The interval can be selected on basis of the age and the most progressed proximal caries lesion which was identified during the latest radiographic caries assessment. While shorter intervals seems to be recommended in patients with high caries risk/activity and more extended lesions, longer intervals can be chosen in less caries-active individuals

## Bitewing radiography

Caries prevalence, experience and risk are declining across many European countries. This, basically, emphasizes the suggestion for reducing the use of bitewing radiographs (Baelum 2010). It seems to be realistic to reduce the number of radiographs taken by applying a more patient-specific, indication-oriented decision-making process for initial assessment (Fig. 2) and monitoring (Table 1) with the aim to move away from generalizing screening recommendations (Espelid et al. 2003; AAPD 2017). Even so, caries is still present in young and adolescent populations and the dental status needs to be assessed at regular intervals (Kühnisch et al. 2016). In such cases bitewing radiographs are beneficial to detect proximal caries in enamel and dentine, to assess occlusal dentine caries lesions and classify the caries extension. Furthermore, residual or secondary caries, the quality of dental restoration as well as indicators of periodontal disease and occlusal stress can be assessed. In addition, it may provide assessment for interproximal bone levels. Image receptor holders should be used to align the X-ray beam to minimize overlapping effects on proximal surfaces and to ensure comparability between different images of the same teeth for caries monitoring. The following statements can be summarized for using bitewing radiographs:

- Clinical indicator for prescribing bitewing radiographs is the presence of active, non-cavitated as well as manifested caries lesions in the primary, mixed or permanent dentition (Fig. 2). The caries risk and activity should be assessed at regular time intervals and may influence the indication to prescribe initial and monitoring bitewing radiographs.
- Intervals for repeating bitewing radiographs (caries monitoring) should be justified on basis of the latest documented caries extent (Table 1). As rule of thumb it can be said the younger the patient and more extended/active the caries the higher seems to be the probability to progress which may indicate shorter monitoring intervals. All means must be carried out to arrest the existing carious lesions (Kühnisch et al. 2016).
- Bitewing radiographs are not indicated for diagnosing periodontitis. However, the presence of localised bone defects at the mesial periodontium of first permanent molars should be reported and evaluated as they might represent an early indicator of periodontitis.
- In children, unable to tolerate intraoral radiography, a PR using a bitewing programme might be considered as an alternative projection technique, even though it is not as precise as the bitewing radiograph.
- X-ray-free alternatives, such as tooth separation or photo-optical diagnostic devices, e.g., near-infrared light transillumination (DIAGNOcam, KaVo, Biberach,

Germany), laser fluorescence (DIAGNOdent, KaVo, Biberach, Germany), fibre-optical transillumination (FOTI) and other fluorescence-based cameras (e.g., VistaCam, Dürr Dental, Bietigheim-Bissingen, Germany), should be taken into account as alternative examination tools before dental radiographs are prescribed, but only with an understanding of their diagnostic efficacy (Pretty and Ekstrand 2016; Kühnisch et al. 2016).

## Diagnostic periapical radiographs

Periapical radiographs are typically chosen to answer questions regarding dental anatomy, e.g., root canal morphology, root development or configuration of the apical foramen, and pathology, e.g., periapical or furcal periodontitis, traumatic dental injuries, inflammatory tooth resorption, replacement resorption, internal/external tooth resorptions or invasive cervical resorptions. Detailed imaging with periapical radiographs might be beneficial in several clinical situations which are summarized below:

- In symptomless, vital primary and permanent teeth with deep caries or in teeth with symptoms of reversible pulpitis, a periapical radiograph is indicated only when bitewing radiography suggests additional pathological findings, and therefore, endodontic treatment or tooth extraction might be potentially indicated.
- In symptomatic and/or non-vital primary teeth with deep caries or other dental pathoses (with or without clinical signs of apical pathology) a periapical radiograph is only needed, when bitewing radiographs are not able to capture the roots sufficiently, when root canal treatment is potentially indicated or when the painful tooth cannot be identified by clinical investigation alone.
- In symptomatic and/or non-vital permanent teeth with deep caries or other dental pathology (with or without clinical signs of apical pathoses) a periapical radiograph is justified to prove the feasibility of endodontic treatment and restorability.
  - At least one periapical radiograph with respect to the clinical situation is indicated after dental trauma in primary and permanent teeth to detect potentially present root fractures and to assess the dental developmental stage which might be of relevance during treatment and monitoring. The earlier published recommendations by the IADT (DiAngelis et al. 2012; Andersson et al. 2012; Malmgren et al. 2012) or its updates should be followed to diagnose, treat and monitor traumatized teeth.
- In teeth with severe anatomical malformations or developmental disorders, e.g., fused teeth or microdontia, or in case of suspected presence of a supernumerary tooth,

- e.g., mesiodens, an intraoral radiograph should be considered first.
- In case of suspected impaction, e.g., a tooth which remains unerupted and non-palpable beyond the expected date of eruption, persistence of the corresponding primary tooth or crowding/orthodontic space closure, a periapical radiograph should be considered first, before a PR.
  - Image receptor holders should be used to align the X-ray beam with the image detector appropriately.

## Workshop 2: Panoramic radiographs (PR)

The PR might be the preferred imaging technique for dental problems which affect larger areas of the jaws. Good cooperation of the patient, including the ability to follow instructions and to remain still for the required exposure time, has to be established as a minimum requirement to ensure an appropriate image quality. This can be expected in young patients around the age of 4 years at the earliest. Some manufacturers allow for a fast scanning mode of the PR machine, which might be considered for patients who cannot stand still long enough for a regular PR exposure. The latter will reduce the chance of motion artefacts and hence increase the diagnostic yield. Unfortunately, there are no comparable imaging techniques available, which allow an X-ray-free presentation. The following clinical indicators may justify PR:

- In patients who cannot tolerate intraoral imaging, PR might be considered as alternative projection technique. However, one has to take into account the inherent image distortion in PR and the presence of ghost images.
- In general, PR is not considered as diagnostic image for assessing initial dental caries in primary, mixed and permanent dentition. However, gross caries lesions can be reliably detected only. In case of severe and extensive tooth decay, dental radiography is mostly needed aiming at assessing caries extension, tooth preservability, presence of infection foci or root development. While intraoral radiographs should be preferred, PR might also be considered.
- In mild acute dental infections (teeth with probable periapical symptoms, e.g., fistula or positive percussion testing), PR is not the radiograph of choice.
- In severe acute periapical or peri-coronal infections—abscesses with intra- and/or extraoral swelling and possibly fever—(unilateral) PR might be considered due to the fact, that intraoral imaging is frequently painful or causes substantial discomfort and is not tolerated by some children.
- PR is considered to be useful following to dentomaxillofacial trauma for the detection of mandible or condylar fractures. However, PR is not recommended to assess dental trauma.
- PR is considered to be useful in identifying generalized dental anomalies, e.g., hypo- or hyperdontia.
- In genetically linked developmental disorders, e.g., amelogenesis/dentinogenesis/osteogenesis imperfecta and (syndromic) patients with generalized pathological condition, typically a full radiographic assessment of the dental status is needed which can be performed by PR.
- Pathological findings, e.g., cysts or tumours, are rare conditions in paediatric dental patients. If an intraoral radiograph reveals uncommon structures or findings, e.g., radiolucent or radiodense areas which can't be explained by anatomy, PR will enable to visualize a larger FOV.
- In patients undergoing extensive medical treatment, e.g., bone marrow/organ transplantation, a dental examination including PR might be used to identify possible infection foci. Site specific intraoral radiographs might still be required though.

## Workshop 3: Cone-beam computed tomography (CBCT)

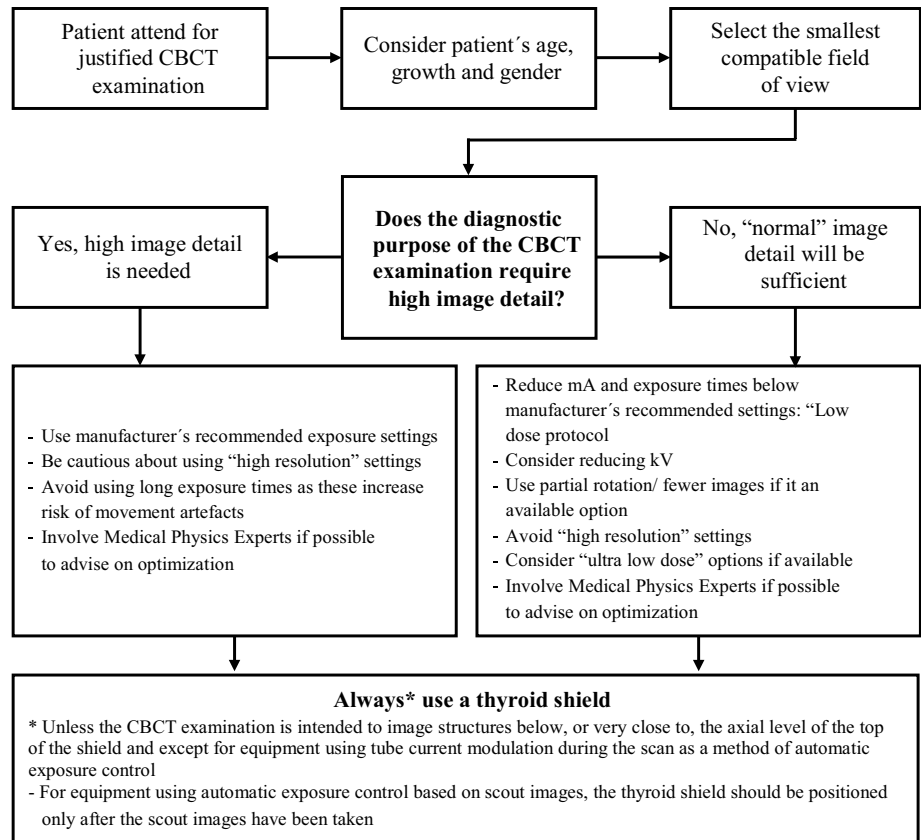
CBCT (Horner et al. 2009; Noffke et al. 2011; EC 2012; Hayashi et al. 2018) can provide detailed cross-sectional images of the teeth and their surrounding tissues. CBCT equipment varies considerably, with some providing only small FOVs (height  $\leq 10$  cm), some only large FOVs (height  $> 15$  cm) and others which can provide a range of FOV sizes. The choice of FOV should reflect the area of diagnostic interest. Recently, some systems can offer a continuously variable FOV, within specified maximum and minimum size limits, which is preferable for matching the field to the clinical region of interest. It is of high importance to recognize that reported effective doses from CBCT procedures in paediatric phantoms are up to 582  $\mu\text{Sv}$  for small-sized scanning volumes to 769  $\mu\text{Sv}$  for medium to large volumes (Ludlow et al. 2015). CBCT examinations can be justified only when it results in a substantial net gain of information which directly influences the decision making.

The following indications were discussed during the EAPD Interim Seminar:

- A flow diagram (Fig. 3) is proposed as a guidance in the choice of device settings when a CBCT is planned.
- CBCT is not the first-line imaging method in children and adolescents and might be justified in a few clinical situations only when cross-sectional imaging is essential for diagnosis and treatment planning in permanent teeth.



**Fig. 3** Guidance to choose device settings when a CBCT is planned



- The FOV of a justified CBCT should be limited as precisely as possible to the area of interest to keep the patient's dose as low as possible.
- CBCT scans should be interpreted and reported by competent and trained professionals. Here, it is essential to point out that not only the area of interest has to be interpreted but also the whole captured volume, which requires a profound knowledge in radiological anatomy and pathology.
- There is no justification to prescribe CBCT for imaging caries lesions. However, scans taken for other purposes should, nevertheless, be examined for caries, albeit with caution, and followed appropriately with further investigations. There is some evidence that cavitation of proximal lesions can be identified more accurately when using CBCT than bitewing images.
- Routine use of CBCT for acute dental infections is not indicated as a standard method. However, in cases where a dental cause of infection remains elusive, CBCT might be considered to aid diagnosis.
- There is insufficient evidence to recommend standardized use of CBCT for any type of acute dental or dentoalveolar trauma. However, it could be considered on a case-by-case basis in severely traumatized permanent teeth, e.g., teeth with multiple fractures, root or crown-root fractures with mobile coronal tooth fragments. In those clinical cases, CBCT might be considered to determine the coronal extent of a root fracture on the palatal aspect as that might influence the treatment plan. Caution is advised when considering the use of CBCT for root fracture diagnosis in the presence of high attenuation materials, e.g., root canal filling materials or metal restorations, in and or around the tooth.
- There is insufficient evidence for use of CBCT in cases of late complications after dental trauma, e.g., inflammatory resorptions, replacement resorptions or ankylosis. However, it could be considered on a case by case basis.
- There is no evidence for the use of CBCT in cases of periodontal diseases in a child population.
- There is little empirical evidence for the use of CBCT to assess cysts, tumours or benign conditions; however, the role of radiology would be to identify the position and integrity of lesion margins and its relationship with adjacent structures.
- In cases of invasive cervical resorption there is some evidence that CBCT might help accurately determine the extent of the lesion as this could potentially influence the treatment decision.
- Evidence shows that CBCT allows more accurate and reliable localisation of maxillary canines with an eruption disturbance than conventional radiographs. It seems reasonable that this could be applied in cases of other

**Table 2** Overview of potential clinical-based indications of dental radiographs in children and adolescents (+ indicated, ± may have some indication, – no indication)

	Bitewing radiograph	Periapical radiographs	Panoramic X-rays	CBCT
Caries detection and diagnosis	Method of 1st choice	+	2nd line: bitewing PR	–
(Acute) Dental infection	–	+	+	–
Dental trauma				
Tooth fractures and luxation injuries	–	Method of 1st choice	–	–
Severe dental trauma: multiple fractured teeth, crown-root fractures, mobile fragments etc.	–	Method of 1st choice	–	±
Complication: tooth resorption	–	Method of 1st choice	–	±
Dental anomalies				
Hypodontia	–	Method of 1st choice, when localized	Method of 1st choice, when generalized	–
Supernumerary teeth	–			
Suspected tooth impaction	–			
Developmental disorders				
Molar-incisor hypomineralisation	–	Method of 1 <sup>st</sup> choice, when one severely affected molar	Method of 1st choice, when > 1 severely affected molar	–
Amelo-/Dentino-/Osteogenesis imperfecta	–	+	Method of 1st choice	±
Cleft lip and palate patients	–	+ or maxillary occlusal projection	+	±
Pathological findings				
Periodontal disease	±	Method of 1st choice, when localized	Method of 1st choice, when generalized	–
Condylar morphology in patients with temporomandibular dysfunction	–	–	+	–
Cysts and benign tumours	–	–	+	±
Invasive cervical resorption	–	+	–	±

unerupted impacted and ectopic teeth. Its use could be considered in cases where it is likely to influence the management and where conventional radiographs fail to provide sufficient information, including assessment of resorption.

- Although there is little evidence for efficacy in cases of dens invaginatus, fusion, dilaceration, gemination and other morphological anomalies, CBCT might add valuable anatomical information aiding management, should conventional radiographs not provide adequate information.
- CBCT is of value in cases of autotransplantation of teeth to produce replica donor teeth and surgical guides.

## Conclusions

Experts and delegates from many European countries discussed fundamental, scientific and clinical aspects of dental radiography in paediatric dentistry. It needs to be pointed out again that there is mostly no or low-grade evidence about diagnostic efficacy from clinical and/or

radiographic studies in young populations. This fact is discouraging with respect to the frequent need of dental radiography in paediatric dental practice and implies that the given recommendations and rationales should be understood as best clinical practice opinions. Besides, it is essential to respect the radiological principle of a patient-specific justification. When a dental X-ray examination is indicated (Table 2), its application needs to be optimized aiming at limiting the patient's exposure to ionising radiation to the lowest level maintaining though an acceptable image quality. Further, EAPD is encouraging manufacturers and researchers to develop X-ray-free diagnostic tools that will allow safe and unrestrictive imaging of oral and dental structures.

**Acknowledgements** The European Academy of Paediatric Dentistry wants to thank the Hellenic Society of Paediatric Dentistry for organizing the 11th EAPD Interim Seminar and Workshop in Chania, Greece May 3rd–4th, 2019 on “Conventional and modern imaging tools in Paediatric Dentistry: from intraoral radiographs to 3D technologies”. Special thanks to the chair of the local organizing committee, Dr. Nick Lygidakis and the president of the Hellenic Society of Paediatric Dentistry, Dr. Sofia Gkeki, as well as all involved in arrangements,

for organizing a successful and memorable seminar. Furthermore, the EAPD wants to express gratitude to all participants of the workshops from the member countries for their valuable contributions.

*Workshop 1 “Intraoral radiography”* A. De Grauwe (Belgium), N. Kokkinos (Cyprus), C. Onisiforou (Cyprus), J. Vasakova (Czech Republic), P. Hess (Denmark), D. Emmanouil (Greece), D. Kavoura (Greece), A. Ní Chaollaí (Ireland), M. Ashkenazi (Israel), C. Silvia (Italy), A. Jacobsen (Norway), M. Tanase (Romania), T. Tomažević (Slovenia), M. Ivanovic (Serbia), N. Sabel (Sweden), S. Selvi Kuvvetli (Turkey), T. Kandiah (UK), O. Hrynyshyn (Ukraine), U. Schiffer (Germany), L.Z. Lim (Singapore, expert), J. Tong (Singapore, expert), J. Aps (Australia, expert), M. Sobczak (Poland, moderator), S. Rajasekharan (Belgium, moderator).

*Workshop 2 “Panoramic radiography”* R. Billen (Belgium), H. Juric (Croatia), P. Kokkinos (Cyprus), V. Merglova (Czech Republic), E. Esclason (France), K. Arapostathis (Greece), Z. Yfanti (Greece), A. Shmueli (Israel), A. Majorana (Italy), I.J. Brusevold (Norway), C. Bica (Romania), T. Leban (Slovenia), Z. Mandinic (Serbia), E. Esclason (Sweden), L. Vasquez (Switzerland), D. Özge Yilmaz (Turkey), P. Ashley (United Kingdom), T. Lysak (Ukraine), K. Tsiklakis (Greece, expert), J. Kühnisch (Germany, moderator, chair of CAC), V. Anttonen (Finland, moderator).

*Workshop 3 “Cone-beam CT”* S. Theys (Belgium), J. Kaiferova (Czech Republic), M.-C. Manière (France), K. Bücher (Germany), A. Mitsea (Greece), D. Finucane (Ireland), E. Davidovich (Israel), S. Friedlander-Barenboim (Israel), G. Fabrizio Ferrazzano (Italy), K. van Nes (Netherlands), A. J. Schmalfluss (Norway), C. Antohi (Romania), L. Hočevár (Slovenia), B. Wondimu (Sweden), D. Dagassan (Switzerland), D. Tabakcilar (Turkey), J. Monteiro (United Kingdom), M. Dolhova (Ukraine), K. Horner (United Kingdom, expert), M. Duggal (Singapore, moderator), E. Stratigaki (Switzerland, moderator).

## Compliance with ethical standards

**Conflict of interest** All authors declare that they have no conflicts of interest.

## References

- American Academy of Pediatric Dentistry (AAPD) Prescribing dental radiographs for infants, children, adolescents, and individuals with special health care needs. 2017. [https://www.aapd.org/globalassets/media/policies\\_guidelines/bp\\_radiographs.pdf](https://www.aapd.org/globalassets/media/policies_guidelines/bp_radiographs.pdf). Accessed Sep 2, 2019.
- Association Dental Association (ADA). Dental radiographic examinations: recommendations for patient selection and limiting radiation exposure. Columbia: American Dental Association; 2012.
- Andersson L, Andreassen JO, Day P, Heithersay G, Trope M, DiAngelis AJ, Kenny DJ, Sigurdsson A, Bourguignon C, Flores MT, Hicks ML, Lenzi AR, Malmgren B, Moule AJ, Tsukiboshi M, International Association of Dental Traumatology. International Association of Dental Traumatology guidelines for the management of traumatic dental injuries. 2. Avulsion of permanent teeth. *Dent Traumatol*. 2012;28:88–96.
- Aps J, Lim LZ, Tong JH, Kalia B, Chou AM: Diagnostic efficacy of and indications for intraoral radiographs in paediatric dentistry: a systematic review. *Eur Arch Paediatr Dent* (in review).
- Baelum V. What is an appropriate caries diagnosis? *Acta Odontol Scand*. 2010;68:65–79.
- Brasil DM, Pauwels R, Coucke W, Haiter-Neto F, Jacobs R. Image quality optimization of narrow detector dental computed tomography for paediatric patients. *Dentomaxillofac Radiol*. 2019. <https://doi.org/10.1259/dmfr.20190032>.
- Canadian Dental Association (CDA). Control of x-radiation in dentistry. *J Can Dent Assoc*. 1999;65:610–1.
- DiAngelis AJ, Andreassen JO, Ebeleseder KA, Kenny DJ, Trope M, Sigurdsson A, Andersson L, Bourguignon C, Flores MT, Hicks ML, Lenzi AR, Malmgren B, Moule AJ, Pohl Y, Tsukiboshi M. International Association of Dental Traumatology guidelines for the management of traumatic dental injuries: 1. Fractures and luxations of permanent teeth. *Dent Traumatol*. 2012;28:2–12.
- Espelid I, Mejåre I, Weerheijm K. EAPD: EAPD guidelines for use of radiographs in children. *Eur J Paediatr Dent*. 2003;4:40–8.
- European Commission (EC). Radiation protection 136. European guidelines on radiation protection in dental radiology. Luxembourg: office for official publications of the European Communities. 2004. <https://ec.europa.eu/energy/sites/ener/files/documents/136.pdf>. Accessed Sep 2, 2019.
- European Commission (EC). Radiation protection 172. Evidence based guidelines on cone beam CT for dental and maxillofacial radiology. Office for official publications of the European Communities: Luxembourg. 2012.
- European Commission (EC). Radiation protection. No 180. Medical radiation exposure of the European population. Luxembourg: Publications Office of the European Union. 2015. <https://ec.europa.eu/energy/sites/ener/files/documents/RP180.pdf>. Accessed Sep 2, 2019.
- Council of the European Union. Basic safety standards for protection against the dangers arising from exposure to ionising radiation, and repealing Directives 89/618/Euratom, 90/641/Euratom, 96/29/Euratom, 97/43/Euratom and 2003/122/Euratom. 2013. <http://data.europa.eu/eli/dir/2013/59/oj>. Accessed Sep 2, 2019.
- Fryback DG, Thornbury JR. The efficacy of diagnostic imaging. *Med Decis Making*. 1991;11:88–94.
- Goodwin TL, Devlin H, Glenny AM, O’Malley L, Horner K. Guidelines on the timing and frequency of bitewing radiography: a systematic review. *Br Dent J*. 2017;222:519–26.
- Hayashi T, Arai Y, Chikui T, Hayashi-Sakai S, Honda K, Indo H, Kawai T, Kobayashi K, Murakami S, Nagasawa M, Naitoh M, Nakayama E, Nikkuni Y, Nishiyama H, Shoji N, Suenaga S, Tanaka R. A committee on clinical practice guidelines, Japanese society for oral and maxillofacial radiology. Clinical guidelines for dental cone-beam computed tomography. *Oral Radiol*. 2018;34:89–104.
- Hidalgo Rivas JA, Horner K, Thiruvengkatachari B, Davies J, Theodorakou C. Development of a low-dose protocol for cone beam CT examinations of the anterior maxilla in children. *Br J Radiol*. 2015;88:20150559.
- Horner K, Barry S, Dave M, Dixon C, Lap PC, Littlewood A, Srinivasan V, Sengupta A. Diagnostic efficacy of cone beam computed tomography in paediatric dentistry: a systematic review. *Eur Arch Paediatr Dent* (in review).
- Horner K, Eaton KA. Faculty of general dental practice (FGDP) of the UK. Selection Criteria for dental Radiography. An updated 3rd edition (2018).
- Horner K, Islam M, Flygare L, Tsiklakis K, Whaites E. Basic principles for use of dental cone beam computed tomography: consensus guidelines of the European academy of dental and maxillofacial radiology. *Dentomaxillofac Radiol*. 2009;38:187–95.
- Jacobs R, Salmon B, Codari M, Hassan B, Bornstein MM. Cone beam computed tomography in implant dentistry: recommendations for clinical use. *BMC Oral Health*. 2018;18:88.
- Kühnisch J, Rahman A, Rahman A, Heinrich-Weltzien R. Röntgendiagnostik in der Kinder- und Jugendzahnmedizin. *Dtsch Zahnärztl Z*. 2018;74:438–46.
- Kühnisch J, Ekstrand K, Pretty I, Twetman S, van Loveren C, Gizani S, Spyridonos M. Best Clinical Practice Guidance for management of early caries lesions in children and young adults. An EAPD policy document. *Eur Arch Paediatr Dent*. 2016;17:3–12.

- Le Heron J. Guidelines on patient dose to promote the optimisation of protection for diagnostic medical exposures: documents of the NRPB. *Radiat Prot News Notes*. 1999;10(1):17–8.
- Ludlow JB, Timothy R, Walker C, Hunter R, Benavides E, Samuelson DB, et al. Effective dose of dental CBCT—a meta analysis of published data and additional data for nine CBCT units. *Dentomaxillofac Radiol*. 2015;44(1):20140197.
- Malmgren B, Andreassen JO, Flores MT, Robertson A, DiAngelis AJ, Andersson L, Cavalleri G, Cohenca N, Day P, Hicks ML, Malmgren O, Moule AJ, Onetto J, Tsukiboshi M, International Association of Dental Traumatology. International Association of Dental Traumatology guidelines for the management of traumatic dental injuries: 3 Injuries in the primary dentition. *Dent Traumatol*. 2012;28:174–82.
- Minister of Public Works and Government Services (Canada). Radiation protection in dentistry recommended safety procedures for the use of dental X-ray equipment (1999).
- National Radiological Protection Board (NRPB). Guidance notes for dental practitioners on the safe use of X-ray equipment. 2001: Department of Health; 2001.
- Noffke C, Nzima N, Farman A. Guidelines for the safe use of dental and maxillofacial CBCT: a review with recommendations for South Africa. *S Afr Dent J*. 2011;66:262–6.
- Oenning AC, Jacobs R, Pauwels R, Stratis A, Hedesiu M, Salmon B, DIMITRA Research group. Cone-beam CT in paediatric dentistry: DIMITRA project position statement. *Pediatr Radiol*. 2018;48:308–16.
- Pauwels R, Horner K, Vassileva J, Rehani MM. Thyroid shielding in cone beam computed tomography: recommendations towards appropriate use. *Dentomaxillofac Radiol*. 2019:20190014.
- Pauwels R, Jacobs R, Bogaerts R, Bosmans H, Panmekiate S. Determination of size-specific exposure settings in dental cone-beam CT. *Eur Radiol*. 2017;27:279–85.
- Pretty IA, Ekstrand KR. Detection and monitoring of early caries lesions: a review. *Eur Arch Paediatr Dent*. 2016;17:13–25.
- Tsiklakis K, Mitsea A, Tsihlaki A, Pandis N. A systematic review of relative indications and contra-indications for prescribing panoramic radiographs in dental paediatric patients. *Eur Arch Paediatr Dent*. 2019. <https://doi.org/10.1007/s40368-019-00478-w>
- Valentin J (ed.): The 2007 recommendations of the international commission on radiological protection. ICRP publication 103. Ann ICRP. 2007. [http://www.icrp.org/docs/ICRP\\_Publication\\_103-Annals\\_of\\_the\\_ICRP\\_37\(2-4\)-Free\\_extract.pdf](http://www.icrp.org/docs/ICRP_Publication_103-Annals_of_the_ICRP_37(2-4)-Free_extract.pdf). Accessed Sep 2, 2019.
- Van Acker JWG, Rajasekharan S, Aps JKM, Pauwels NS, Cauwels RGEC: Outcomes of different radioprotective precautions in children undergoing dental radiography, a systematic review of the literature. *Eur J Paediatr Dent* (in review).
- White SC, Scarfe WC, Schulze RK, Lurie AG, Douglass JM, Farman AG, Law CS, Levin MD, Sauer RA, Valachovic RW, Zeller GG, Goske MJ. The image gently in dentistry campaign: promotion of responsible use of maxillofacial radiology in dentistry for children. *Oral Surg Oral Med Oral Pathol Oral Radiol*. 2014;118:257–61.
- White SC, Heslop EW, Hollender LG, Mosier KM, Ruprecht A, Shroud MK, American Academy of Oral and Maxillofacial Radiology, ad hoc Committee on Parameters of Care. Parameters of radiologic care: an official report of the American academy of oral and maxillofacial radiology. *Oral Surg Oral Med Oral Pathol Oral Radiol Endod*. 2001;91:498–511.

**Publisher's Note** Springer Nature remains neutral with regard to jurisdictional claims in published maps and institutional affiliations.